Case Series

Synergistic use of robotic navigational platform and ultrathin bronchoscopy in diagnostic yield optimization for cavitary lung lesions: a case series

Rodrigo Garcia Tome^

Los Angeles General Medical Center + University of Southern California, Los Angeles, CA, USA

Correspondence to: Rodrigo Garcia Tome, MD. Los Angeles General Medical Center + University of Southern California, 2020 Zonal Avenue, IRD 723, Los Angeles, CA 90033, USA. Email: Rgarciatome@dhs.Lacounty.gov.

Background: Cavitary lung lesions represent a diagnostic challenge due to their heterogeneous etiology, which includes infectious, inflammatory, and malignant processes. Establishing an accurate diagnosis is essential, yet conventional techniques such as computed tomography-guided transthoracic biopsy, surgical biopsy and standard bronchoscopy may be limited by complication risk or suboptimal yield. Recent advances in robotic and ultrathin bronchoscopy have improved precision and reach, but their combined application remains underexplored.

Case Description: We conducted a retrospective case series of six consecutive patients with cavitary lung lesions evaluated at a tertiary academic medical center. All procedures were performed by a single interventional pulmonologist using a standardized workflow. Pre-procedural lesion marking and airway mapping were completed in all cases with Intuitive PointPlan software to generate a virtual navigation roadmap. Ultrathin flexible bronchoscopy (Vathin disposable bronchoscope; 3.2-mm outer diameter, 1.2-mm working channel) was used in all patients to access and sample the target cavities. In four cases performed under general anesthesia, the IonTM robotic bronchoscopy platform was additionally employed for navigational guidance and fluoroscopy-assisted biopsy, followed by ultrathin bronchoscopy to allow direct intracavitary visualization and targeted sampling. Successful navigation to the cavitary lesion was achieved in all six procedures. The combined robotic-ultrathin bronchoscopy approach provided additional diagnostic information beyond robotic-guided sampling alone in two of four cases. No procedure-related pneumothorax or significant bleeding occurred. One patient developed a transient post-procedural fever that resolved with antibiotic therapy. At 3-month follow-up, all patients demonstrated radiologic or symptomatic improvement consistent with the final diagnosis.

Conclusions: The combined use of navigational robotic and ultrathin flexible bronchoscopy is a feasible, safe, and potentially superior approach for evaluating cavitary lung lesions. This workflow integrates precise navigation with direct intracavitary visualization, optimizing diagnostic yield while minimizing procedural risk.

Keywords: Cavitary lung lesions; robotic bronchoscopy; ultrathin bronchoscopy; innovation in bronchoscopy; case series

Submitted Oct 08, 2025. Accepted for publication Dec 03, 2025. Published online Feb 10, 2026.
doi: 10.21037/jtd-2025-aw-2052
View this article at: https://dx.doi.org/10.21037/jtd-2025-aw-2052

^ ORCID: 0000-0002-2658-971X.

© AME Publishing Company.

Introduction

As defined by the Fleischner Society, lung cavities constitute a gas-filled space within a nodule, mass, or area of consolidation, characterized by a wall thickness greater than 4 mm (1). Its differential diagnosis is broad, spanning infections, inflammatory conditions, malignancies, among others. Common infectious etiologies include *Staphylococcus aureus* and *Mycobacterium tuberculosis*, while fungal and parasitic organisms are also implicated. Inflammatory causes include granulomatosis with polyangiitis, rheumatoid arthritis, and sarcoidosis. Both primary lung cancers, particularly squamous cell carcinoma, and metastatic malignancies can present with cavitary morphology (1,2).

Cavitary lung lesions represent a distinct diagnostic challenge because of their heterogeneous presentations and diverse causes. Given the broad differential diagnosis, establishing an accurate diagnosis is essential (2). Broadly, there are three primary approaches to biopsy these lesions, they include bronchoscopic techniques, computed tomography-guided transthoracic biopsy (CTTB), and surgical approach. Within the bronchoscopic field, both flexible and robotic navigational platforms have been used successfully to access and sample these lesions with favorable safety profiles. However, the combined use of ultrathin flexible bronchoscopy and navigational guidance remains underexplored, despite its potential to enhance diagnostic yield while maintaining procedural safety and simplicity.

In this manuscript we describe a workflow that integrates robotic and ultrathin flexible bronchoscopy within a single procedural session, designed to optimize diagnostic yield in cavitary lung lesions. The rationale for this approach lies in leveraging the roadmap created by navigational platforms to access the lesion and then employing ultrathin bronchoscopy to visualize the cavity directly and obtain targeted biopsies. By doing so, the operator benefits from both precise trajectory guidance and direct visualization, thereby overcoming limitations of each modality in isolation with a minimalistic tool footprint. This article is presented in accordance with the AME Case Series reporting checklist (available at https://jtd.amegroups.com/article/view/10.21037/jtd-2025-aw-2052/rc).

Highlight box

Key findings

- This study presents a novel bronchoscopic workflow combining robotic navigation system and ultrathin flexible bronchoscopy to optimize the diagnostic yield of cavitary lung lesions. Using a robotic platform software to create a navigation pathway, an ultrathin bronchoscope was successfully guided into the target cavity in all six cases, enabling direct intracavitary visualization and precise tissue sampling. Furthermore, ultrathin bronchoscopy enhanced the diagnostic yield after standard biopsy procedure with robotic platform in half of the combined cases. No pneumothorax, bleeding, or major complications occurred, and all patients demonstrated radiological improvement at follow-up.

What is known and what is new?

- Cavitary lung lesions represent a diagnostic challenge due to their complex structure and broad differential diagnosis. Traditional modalities such as computed tomography-guided, surgical biopsy and standard bronchoscopy have limitations due to procedural risk and suboptimal diagnostic yield.
- This study introduces a synergistic workflow that combines navigational precision from robotic software guidance with direct intracavitary visualization via ultrathin bronchoscopy. This integrated approach enhances diagnostic accuracy while maintaining procedural safety and efficiency.

What is the implication, and what should change now?

- The combined use of robotic and ultrathin bronchoscopy offers a feasible, safe, and reproducible method for diagnosing cavitary lung lesions. Its versatility under both general anesthesia and moderate sedation supports broad clinical applicability. Further studies should validate its diagnostic yield, safety profile, and cost-effectiveness in larger patient cohorts.

Case presentation

A retrospective case series was assembled including six consecutive patients with cavitary lung lesions requiring tissue and microbiological diagnosis. This case series was conducted in accordance with the Declaration of Helsinki and its subsequent amendments. The case series was approved by the University of Southern California Institutional Review Board (IRB) (No. HS-25-00578). Publication of this case series, accompanying images, and video was waived from patients'/participants' consent according to the ethics committee due to the retrospective nature of this case series and the use of de-identified data. All procedures were performed within a 1-month period, encompassing both inpatient and outpatient referrals to the Interventional Pulmonology Service at Los Angeles General Medical Center, a tertiary academic institution and the largest county hospital in the city. All cases were performed by the same interventional pulmonology attending physician. Inclusion criteria were clearly defined: patients aged 18 years or older were eligible for inclusion, while pregnant patients were excluded. All procedures were conducted in the endoscopy suite. The type of procedural

© AME Publishing Company.

Video 1 Detailed representation of the procedural workflow combining robotic and ultrathin bronchoscopy to optimize diagnostic yield in cavitary lung lesions.

sedation or anesthesia was determined according to case complexity, anesthesiologist availability and individual anesthesiologist preference, ranging from moderate sedation to general anesthesia (GA) with total intravenous anesthesia (TIVA) via a single lumen endotracheal tube (ETT).

Navigation to the target lesion was accomplished using the Intuitive PlanPoint software. The lesion of interest was identified, and a virtual roadmap was generated to define the most efficient airway trajectory and optimal endobronchial angle of approach. Two bronchoscopic instruments were employed based on procedural conditions: a Vathin ultrathin disposable bronchoscope (3.2-mm outer diameter/1.2-mm inner diameter) was used in all six cases, irrespective of the sedation or anesthesia type, whereas the Ion™ robotic bronchoscopy platform (Intuitive Surgical, Synnyvale, USA) was utilized exclusively in the four cases performed under GA.

In cases combining both modalities, the robotic catheter was first advanced to the lesion, and standard tissue sampling was performed under fluoroscopic guidance. Following biopsy completion, the catheter was withdrawn, and the ultrathin bronchoscope was introduced along the same navigational pathway. The ultrathin bronchoscope enabled direct visualization of the lesion interior and facilitated selective or extensive targeted biopsies along the cavity wall with high precision. Its working channel accommodated small biopsy forceps and cryoprobes for tissue acquisition, as well as intracavitary fluid aspiration when indicated. Procedural workflow is shown in *Figure 1*.

Procedural success was defined as successful advancement of the ultrathin bronchoscope into the target cavity under navigational guidance from the Intuitive PlanPoint software. Furthermore, enhanced diagnostic yield was defined as the acquisition of additional diagnostic information obtained with the ultrathin bronchoscope following robotic-guided biopsies, when applicable. This combined workflow was exclusively utilized in the four cases performed under GA.

Follow-up was performed 3 months after the procedure to assess radiographic and symptomatic improvement. Patient demographics, procedural characteristics, and outcomes are summarized in *Table 1*.

Figures 2-7 illustrate in detail the synergistic bronchoscopic technique applied in six consecutive cases over the course of 1 month, aimed at optimizing diagnostic yield in cavitary lung lesions. *Video 1* further demonstrates and complements the procedural workflow.

The mean patient age was 46.6 years, and all six individuals had an American Society of Anesthesiologists (ASA) physical status classification of III, indicating underlying medical comorbidities. Three patients (50%) were living with human immunodeficiency virus (HIV) infection, and the remaining three had a known history of malignancy. In five of six cases (83.3%), the cavitary lesions were of infectious etiology, while one case was attributed to metastatic cancer. Two-thirds of the procedures were performed under GA with TIVA, and one-third were performed under moderate sedation.

The Intuitive PlanPoint virtual navigation software was utilized in all cases for target identification, trajectory optimization, and entry angle determination. Target sizes ranged from 2.8 to 13.8 cm. Successful navigation to the lesion using the combined PlanPoint software and ultrathin bronchoscope was achieved in all cases (100%), allowing for direct intracavitary visualization and targeted sampling, including tissue acquisition and lavage.

In the two cases performed under moderate sedation, only the ultrathin bronchoscope was used in conjunction with the PlanPoint software, without robotic bronchoscopy. In the remaining four cases, the procedures were planned using PlanPoint followed by access with the Ion robotic bronchoscopy system, after which ultrathin bronchoscopy was employed for intracavitary inspection and additional sampling. In two of these four cases (50%), the ultrathin bronchoscope provided additional diagnostic information beyond that obtained by robotic bronchoscopy, suggesting a potential improvement in diagnostic yield with the combined approach.

No pneumothorax or procedure-related bleeding occurred in any case. One patient developed transient

© AME Publishing Company.

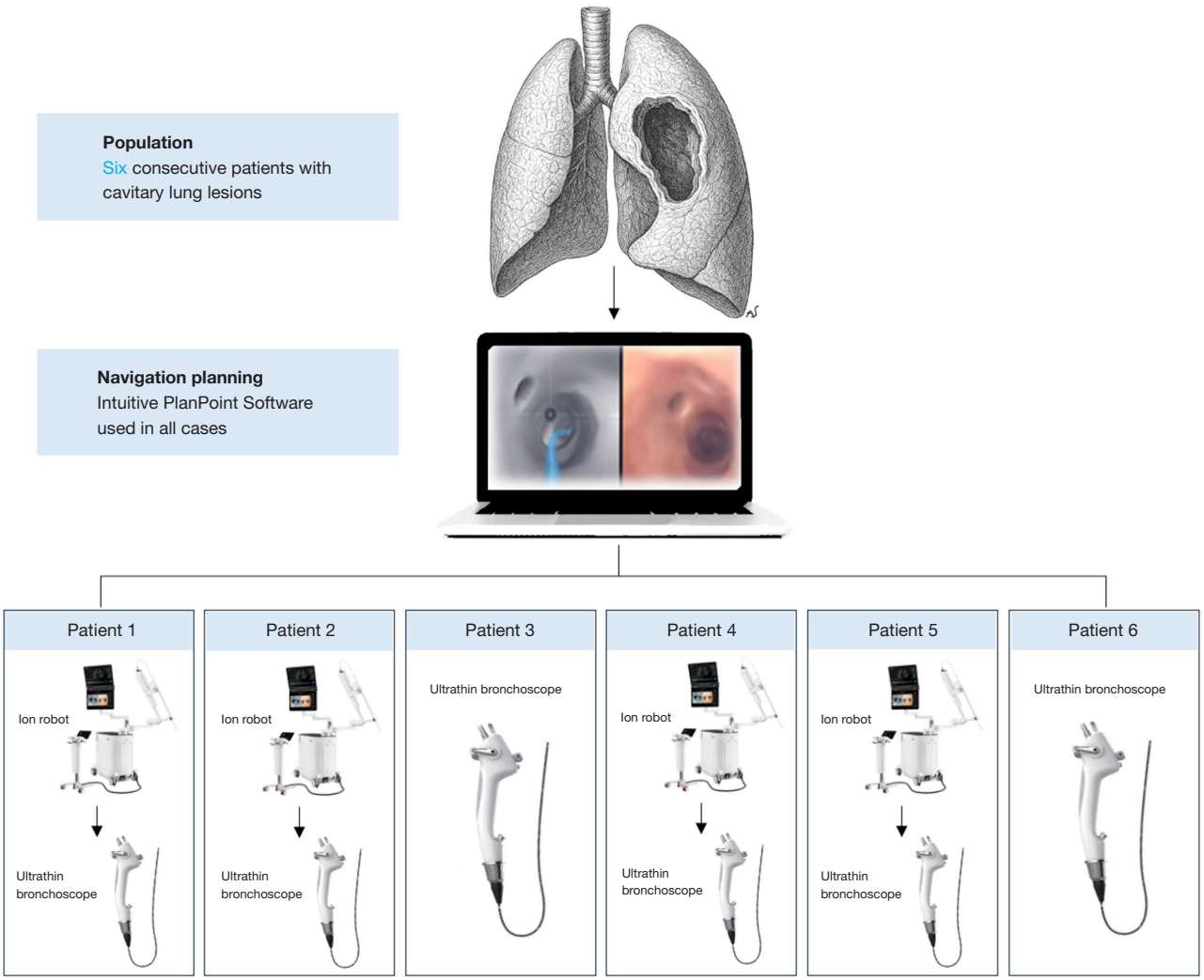

Figure 1 Procedural workflow. Six patients with cavitary lung lesions were referred within a 1-month period to the Interventional Pulmonology Service. All cases underwent navigational planning using the Intuitive PlanPoint software. Tissue sampling was performed either through Ion™ robotic bronchoscopy followed by ultrathin flexible bronchoscopy, or solely with ultrathin bronchoscopy in cases conducted under moderate sedation. Illustration courtesy of Alito Suequito. Equipment images obtained from www.intuitive.com and www.vathin.com.

fever and increased radiographic opacities within 72 hours post-procedure; however, the patient's symptoms resolved following initiation of targeted antibiotic therapy. At 3-month follow-up, all patients demonstrated either stabilization or radiologic improvement of their cavitary lesions, corresponding to appropriate treatment of the underlying pathology.

Discussion

Given the broad differential diagnosis of cavitary lung lesions, establishing an accurate diagnosis is essential (2). While radiographic features can offer valuable diagnostic clues, they are rarely definitive (1). Findings such as the halo sign, reversed halo sign, and variable cavitation patterns may help narrow the differential; however, tissue sampling remains indispensable for confirmation. Without biopsy, malignant disease may be missed or its diagnosis delayed, potentially leading to significant clinical consequences (3).

CTTB has long been considered a reliable diagnostic modality for cavitary lung lesions, demonstrating an accuracy ranging from 81% to 96% (4,5). However, this

© AME Publishing Company.

Table 1 Patient demographics, procedural characteristics, and outcomes of six consecutive cases using a combined robotic platform and ultrathin flexible bronchoscopy approach

Variables	Patient 1	Patient 2	Patient 3	Patient 4	Patient 5	Patient 6
Sex	Male	Male	Male	Male	Male	Female
Age (years)	48	56	36	64	41	35
ASA	III	III	III	III	III	III
Relevant comorbidities	SCC of the tongue	Stage IV RCC	Poorly controlled HIV	CLL	HIV	Poorly controlled HIV
Outpatient/inpatient	Outpatient	Outpatient	Outpatient	Outpatient	Inpatient	Inpatient
Use of fluoroscopy	Yes	Yes	Yes	Yes	Yes	Yes
Anesthesia type	TIVA	TIVA	Moderate sedation	TIVA	TIVA	Moderate sedation
Use of the Intuitive PointPlan virtual navigation "roadmap"	Yes	Yes	Yes	Yes	Yes	Yes
Successful navigation within the target using the combined PointPlan software and the ultrathin bronchoscope	Yes	Yes	Yes	Yes	Yes	Yes
Tools used for sampling with the Ion robotic system	Yes. Intuitive 21G FNA, Radial Jaw™ 4 Pulmonary biopsy forceps 2 mm, ERBE cryoprobe 1.1 mm	Yes. Intuitive 21G FNA, Radial Jaw™ 4 Pulmonary biopsy forceps 2 mm	No	Yes. Intuitive 21G FNA, Radial Jaw™ 4 Pulmonary biopsy forceps 2 mm, ERBE cryoprobe 1.1 mm	Yes. Intuitive 21G FNA, Radial Jaw™ 4 Pulmonary biopsy forceps 2 mm	No
Tools used for sampling with the ultrathin flexible bronchoscope	Disposable bronchoscope Vathin 3.2/1.2 OD/ID. SpyBite™ Max Biopsy Forceps. ERBE cryoprobe 1.1 mm. Intracavitary BAL	Disposable bronchoscope Vathin 3.2/1.2 OD/ID. SpyBite™ Max Biopsy Forceps. Intracavitary BAL	Disposable bronchoscope Vathin 3.2/1.2 OD/ID. SpyBite™ Max Biopsy Forceps. Intracavitary BAL	Disposable bronchoscope Vathin 3.2/1.2 OD/ID. SpyBite™ Max Biopsy Forceps. Intracavitary BAL	Disposable bronchoscope Vathin 3.2/1.2 OD/ID. SpyBite™ Max Biopsy Forceps. Intracavitary BAL	Disposable bronchoscope Vathin 3.2/1.2 OD/ID. SpyBite™ Max Biopsy Forceps. Intracavitary BAL
Diagnosis obtained by robotic platform	Rare atypical cells suggestive of metastatic SCC	*Aspergillus fumigatus*	N/A	*Staphylococcus aureus*	Mycobacterium avium-intracellular complex	N/A
Diagnosis obtained by flexible bronchoscopy	Metastatic SCC	*Aspergillus fumigatus*	*Klebsiella pneumoniae*	CMV + *Staphylococcus aureus*	Mycobacterium avium-intracellular complex	CMV + polymicrobial infection: *Bordetella bronchiseptica*, *Providencia rettgeri* and *Achromobacter*
Enhanced yield by combination of both sampling techniques	Yes	None	N/A	Yes	None	N/A
Complications	None	None	None	None	Fevers and increased opacities in CXR within 72 hours. Resolution of symptoms and opacities after treatment initiation	None
Chest imaging follow-up at 3 months showing improvement after initiation of tailored treatment	Yes	Yes	Yes	Yes	Yes	Yes

ASA, American Society of Anesthesiologists; BAL, bronchoalveolar lavage; CLL, chronic lymphocytic leukemia; CMV, cytomegalovirus; CXR, chest X-ray; FNA, fine needle aspirate; G, gauge; HIV, human immunodeficiency virus; mm, millimeters; OD/ID, outer diameter/Inner diameter; RCC, renal cell carcinoma; SCC, squamous cell carcinoma; TIVA, total intravenous anesthesia.

© AME Publishing Company.

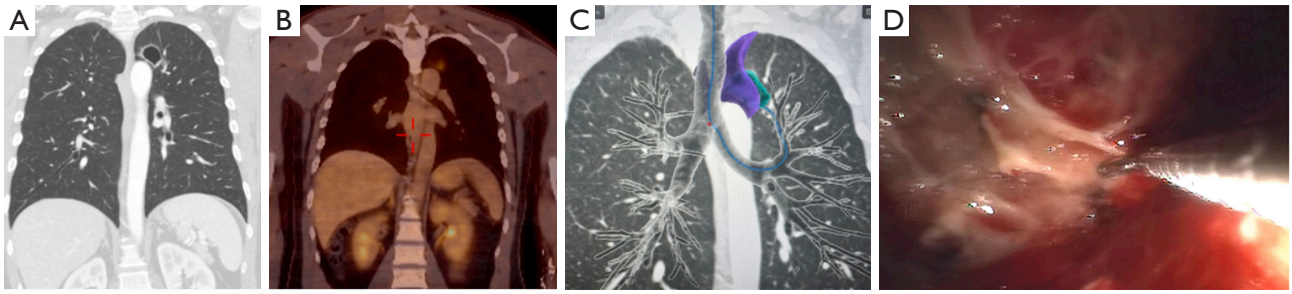

Figure 2 Synergistic use of ultrathin flexible bronchoscopy and robotic platform in the diagnosis of a metastatic squamous cell carcinoma. (A) Cavitary lesion in the left upper lobe with irregular wall thickness. (B) PET demonstrating increased metabolic activity adjacent to the aorta. (C) Robotic bronchoscopy virtual planning showing the target and optimal airway pathway. (D) Direct visualization of the cavity using ultrathin bronchoscopy. Targeted biopsies were obtained from areas of wall thickening that correlated with hypermetabolic regions on PET, which were diagnostic for metastatic disease in this patient. PET, positron emission tomography.

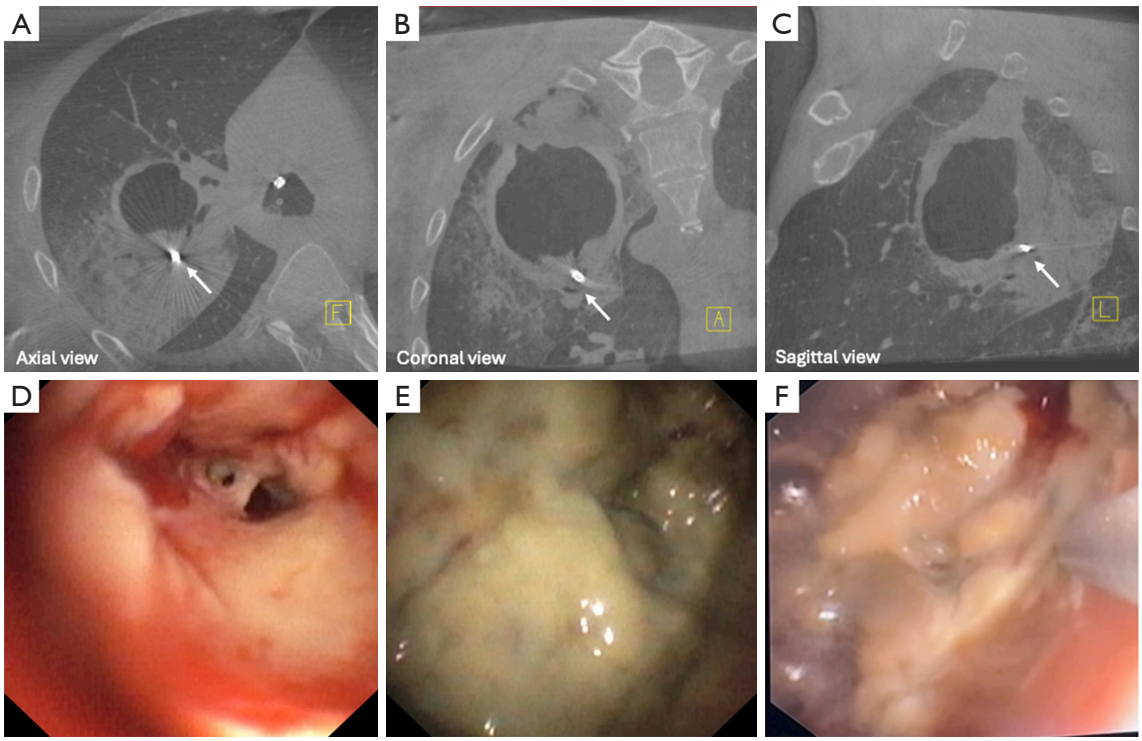

Figure 3 Synergistic use of ultrathin flexible bronchoscopy and robotic platform in the diagnosis of pulmonary aspergillosis. (A-C) Different views of the intraoperative three-dimensional fluoroscopic images, showing the robotic catheter within the lesion (arrows). (D) Bronchoscopic view of the cavity entrance. (E) Bronchoscopic view of the apical wall inside the cavity. (F) Bronchoscopic view of the posterior wall inside the cavity showing a fluid level.

technique is limited by its reliance on needle-based tissue acquisition and is associated with higher complication rates, particularly pneumothorax and hemorrhage when compared with bronchoscopic approaches (4,5). Robotic-assisted bronchoscopy with cone-beam CT has emerged as a promising alternative, offering precision targeting and a more favorable safety profile (2). In one study of 52 patients, robotic-assisted bronchoscopy achieved a diagnostic yield of 83%, with high sensitivity for malignancy and a complication rate of only 4% (4). Despite these encouraging

© AME Publishing Company.

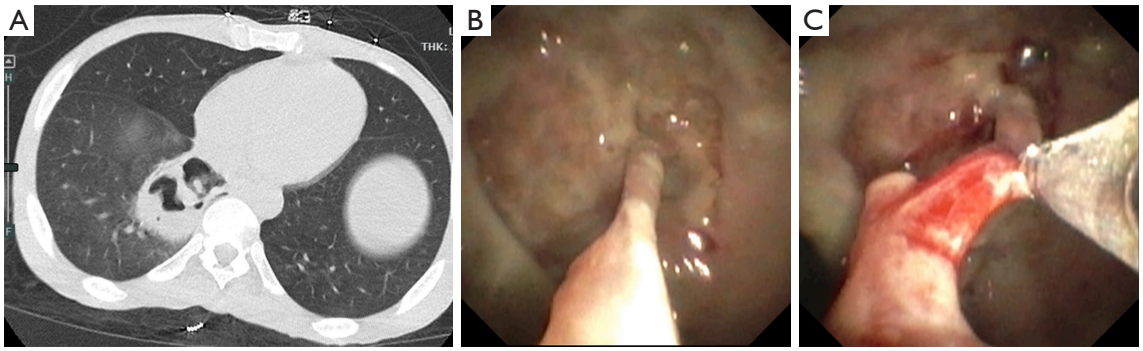

Figure 4 Synergistic use of ultrathin flexible bronchoscopy and robotic virtual airway mapping in the diagnosis of *Klebsiella pneumoniae* infection. (A) Cavitary lesion seen on preoperative computed tomography. (B) Successful navigation within the cavity target after following the virtual path created by the robotic platform software. (C) Intracavitary forceps biopsy, tissue sampled corresponding with the string-shaped tissue present in the center of the cavity in (A).

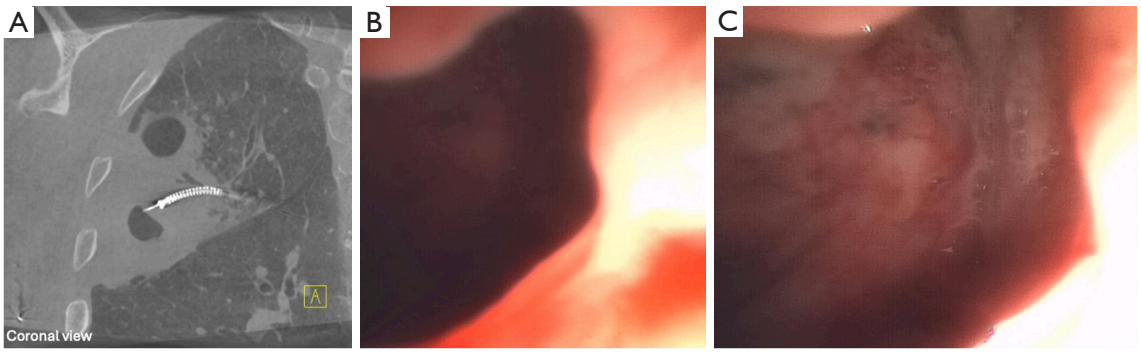

Figure 5 Synergistic use of ultrathin flexible bronchoscopy and robotic platform in the diagnosis of *Cytomegalovirus* and *Staphylococcus* aureus infection. (A) Intraoperative three-dimensional fluoroscopic image showing the robotic catheter and 21G needle within the lesion. (B,C) Bronchoscopic view at the cavity entrance. G, gauge.

results, the absence of direct visualization during biopsy with certain platforms may limit the precision and adequacy of tissue sampling. Conversely, systems that enable visual guidance often require larger catheter sizes, which may increase the risk of tissue disruption in already fragile parenchyma.

Flexible bronchoscopy capabilities have advanced considerably, with the development of thin and ultrathin instruments. Typically defined as bronchoscopes with outer diameters of less than 4.0 and 3.5 mm, respectively, these devices enable deeper navigation within the bronchial tree, reaching up to the ninth generation of airways or beyond (6). Their reduced caliber facilitates access to peripheral nodules and the interior of cavitary lesions. When combined with adjunctive technologies such as fluoroscopy or radial endobronchial ultrasound (r-EBUS), their diagnostic yield is further enhanced (7). The ultrathin bronchoscope, in particular, with its narrower working channel, allows for precise, site-specific sampling within cavitary lesions and has demonstrated additional diagnostic value (7).

Despite these technological advances, several challenges persist in the biopsy of cavitary lung lesions. Because they are rarely homogeneous, the disease of interest may not be evenly distributed across the cavity wall. Necrotic or liquefied centers often fail to provide diagnostic material, resulting in nondiagnostic biopsies even when targeting is precise. Robotic systems also present unique challenges. The Ion platform (Intuitive), while offering the smallest catheter size in the market at 3.5 mm, does not provide direct visualization during biopsy, requiring reliance on fluoroscopy. Other platforms, such as the Galaxy (Noah Medical, San Carlos, USA) and Monarch (Johnson &

© AME Publishing Company.

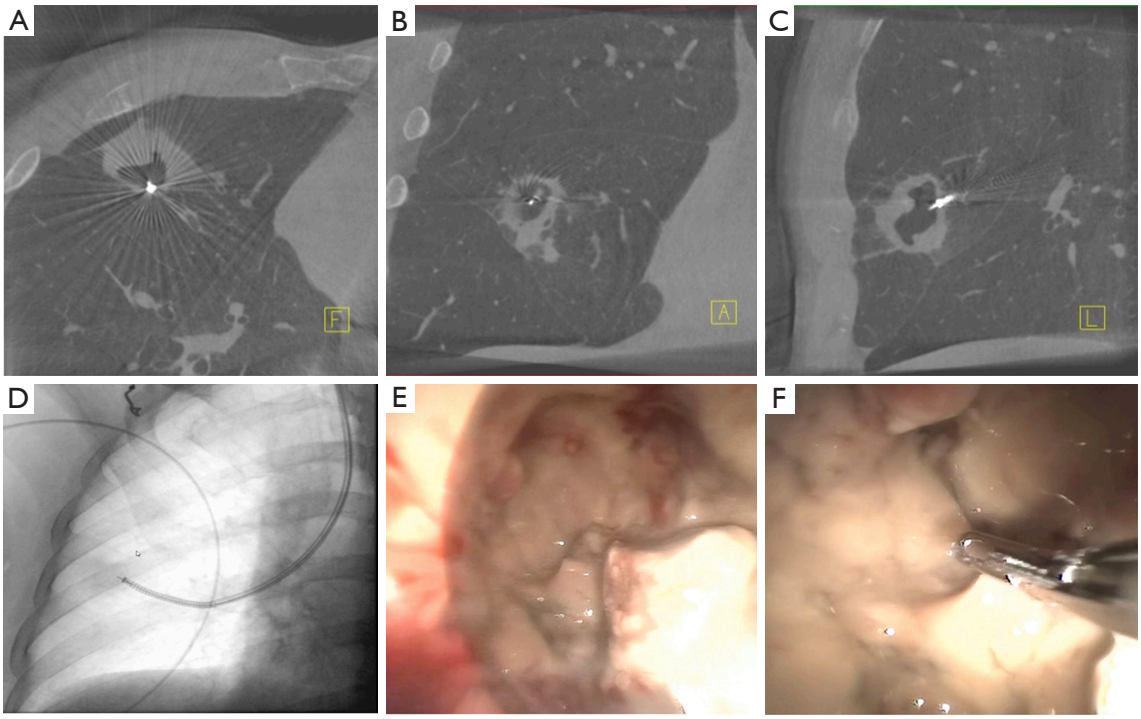

Figure 6 Synergistic use of ultrathin flexible bronchoscopy and robotic platform in the diagnosis of Mycobacterium avium-intracellular complex infection. (A-C) Different views of the intraoperative three-dimensional fluoroscopic images, showing the robotic catheter within the lesion. (D) Two-dimensional fluoroscopic image while performing biopsies with the robotic platform. (E) Bronchoscopic view of the cavity entrance. (F) Selective biopsy of the largest nodular lesion within the cavity with ultrathin flexible bronchoscopy.

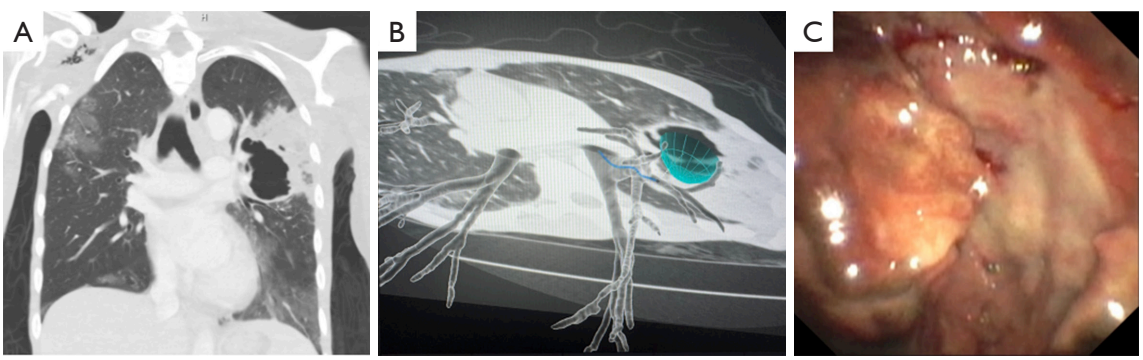

Figure 7 Synergistic use of ultrathin flexible bronchoscopy and robotic virtual airway mapping in the diagnosis of cytomegalovirus and polymicrobial infection. (A) Cavitary lesion seen on preoperative computed tomography. (B) Virtual path created by the robotic platform software showing the optimal airway leading to the target and optimal entry angle. (C) Successful navigation within the cavity target after following the virtual path created by the robotic platform software.

Johnson, Santa Clara, USA), offer visualization but require larger catheters that may further disrupt fragile tissue. Exclusive reliance on flexible bronchoscopy without navigational support can also be problematic, as reaching the lesion and achieving optimal spatial orientation can be difficult. Furthermore, cavitary lesions often carry an elevated risk of pneumothorax or hemorrhage compared with noncavitary lesions, particularly when malignant (2). These

© AME Publishing Company.

limitations highlight the need for approaches that combine the strengths of navigational precision with the visual and sampling capabilities of ultrathin flexible bronchoscopy.

In this manuscript, we describe a workflow that integrates robotic and ultrathin flexible bronchoscopy within a single procedural session, designed to maximize diagnostic yield in cavitary lung lesions. The rationale for this approach lies in leveraging the roadmap created by navigational platforms to access the lesion and then employing ultrathin bronchoscopy to visualize the cavity directly and obtain targeted biopsies. By doing so, the operator benefits from both precise trajectory guidance and direct visualization, thereby overcoming limitations of each modality in isolation with a minimalistic tool footprint.

The potential advantages of this combined approach are several. Diagnostic yield is optimized by combining precise navigational targeting with the ability to visualize and selectively sample viable tissue. Radiation exposure is reduced because reliance on fluoroscopy is diminished. The heterogeneity of cavitary lesions can be addressed by directly targeting different areas within the same cavity, improving the likelihood of identifying pathology. Direct visualization enhances safety by allowing operators to see the site of biopsy, reducing the risk of inadvertent injury. The flexibility of tool selection under direct vision further broadens sampling options (forceps, cryoprobe, etc.). Importantly, this workflow integrates seamlessly into routine practice without requiring additional equipment or major changes to procedural logistics.

Another important advantage of this approach is its adaptability to different clinical environments. In settings where GA is not available, the roadmap created by the navigational platform can be used with flexible bronchoscopy under moderate sedation or topical anesthesia. This feature may be particularly relevant in resource-limited settings, where anesthetic support is restricted.

These promising outcomes suggest that the method is both feasible and safe. Nonetheless, we acknowledge that this represents a preliminary experience, and larger studies are warranted to further validate these findings.

Conclusions

Cavitary lung lesions are diagnostically challenging because of their broad differential diagnosis, heterogeneous internal architecture, and elevated risk of complications during biopsy. Conventional approaches such as CTTB and surgical biopsy carry higher complication rates, while bronchoscopic modalities, though safer, may be limited by limited direct visualization or suboptimal yield.

The combination of navigational robotic bronchoscopy with ultrathin flexible bronchoscopy provides a practical solution by integrating the strengths of both modalities. Navigation establishes a precise roadmap and trajectory, while ultrathin bronchoscopy enables direct visualization and targeted sampling of viable tissue. Together, they create a synergistic workflow that could enhance diagnostic yield, reduces reliance on fluoroscopy, and integrates easily into existing procedural routines.

Our early institutional experience demonstrates the feasibility of this method, with successful outcomes in consecutive cases. These findings provide a foundation for broader clinical validation and integration. Future studies are warranted to formally evaluate diagnostic yield, safety, and cost-effectiveness across larger patient cohorts.

Acknowledgments

The author wishes to acknowledge Dr. Carolina Hurtado for her invaluable mentorship and guidance, without which this work would not have been possible.

Footnote

Reporting Checklist: The author has completed the AME Case Series reporting checklist. Available at https://jtd.amegroups.com/article/view/10.21037/jtd-2025-aw-2052/rc

Peer Review File: Available at https://jtd.amegroups.com/article/view/10.21037/jtd-2025-aw-2052/prf

Funding: None.

Conflicts of Interest: The author has completed the ICMJE uniform disclosure form (available at https://jtd.amegroups.com/article/view/10.21037/jtd-2025-aw-2052/coif). The author has no conflicts of interest to declare.

Ethical Statement: The author is accountable for all aspects of the work in ensuring that questions related to the accuracy or integrity of any part of the work are appropriately investigated and resolved. The case series was conducted in accordance with the Declaration of Helsinki and its subsequent amendments. The case series was approved by the University of Southern California

© AME Publishing Company.

Institutional Review Board (IRB) (No. HS-25-00578). Publication of this case series, accompanying images, and video was waived from patients'/participants' consent according to the ethics committee due to the retrospective nature of this case series and the use of de-identified data.

Open Access Statement: This is an Open Access article distributed in accordance with the Creative Commons Attribution-NonCommercial-NoDerivs 4.0 International License (CC BY-NC-ND 4.0), which permits the non-commercial replication and distribution of the article with the strict proviso that no changes or edits are made and the original work is properly cited (including links to both the formal publication through the relevant DOI and the license). See: https://creativecommons.org/licenses/by-nc-nd/4.0/.

References

1. Gafoor K, Patel S, Girvin F, et al. Cavitary Lung Diseases: A Clinical-Radiologic Algorithmic Approach. Chest 2018;153:1443-65.
2. Boster JM, Goertzen SM, Armas Villalba AJ, et al. Cone-Beam Computed Tomography-guided, Robotic-assisted Bronchoscopy: A Novel Transcavitary Lung Biopsy Approach. Ann Am Thorac Soc 2025;22:938-41.
3. Fujita K, Uchida N, Horimoto K, et al. Two cases of cavitary lung cancer with concomitant chronic infectious disease. Respir Med Case Rep 2018;24:122-4.
4. Fernandez-Bussy S, Funes-Ferrada R, Yu Lee-Mateus A, et al. Diagnostic performance of Shape-Sensing Robotic-Assisted bronchoscopy with mobile Cone-Beam CT for cystic and cavitary pulmonary lesions. Lung Cancer 2024;198:108029.
5. Shin KE, Park JS, Lee JW. Diagnostic Accuracy of CT-Guided Core Needle Biopsy for Thin-Walled Cavitary Pulmonary Lesions. AJR Am J Roentgenol 2021;216:369-75.
6. Katsis JM, Rickman OB, Maldonado F, et al. Bronchoscopic biopsy of peripheral pulmonary lesions in 2020: a review of existing technologies. J Thorac Dis 2020;12:3253-62.
7. Bose S, Ghatol A, Eberlein M, et al. Ultrathin bronchoscopy in the diagnosis of peripheral cavitary lung lesions. J Bronchology Interv Pulmonol 2013;20:167-70.

Cite this article as: Tome RG. Synergistic use of robotic navigational platform and ultrathin bronchoscopy in diagnostic yield optimization for cavitary lung lesions: a case series. J Thorac Dis 2026;18(2):157. doi: 10.21037/jtd-2025-aw-2052